

**DERMATOMAL SOMATOSENSORY EVOKED POTENTIAL  
DEMONSTRATION OF NERVE  
ROOT DECOMPRESSION  
AFTER VAX-D THERAPY**

William K. Naguszewski, Robert K. Naguszewski, and Earl E. Gose \*

*Department of Neurology, Coosa Medical Group, Rome, Georgia, USA*

*\*Department of Bioengineering, University of Illinois at Chicago, Chicago, IL, USA*

*Journal of Neurological Research Volume 23, Number 7, October 2001*

Reductions in low back pain and referred leg pain associated with a diagnosis of herniated disc, degenerative disc disease or facet syndrome have previously been reported after treatment with a VAX-D table, which intermittently distracts the spine. The object of this study was to use dermatomal somatosensory evoked potentials (DSSEPs) to demonstrate lumbar root decompression following VAX-D therapy. Seven consecutive patients with a diagnosis of low back pain and unilateral or bilateral L5 or S1 radiculopathy were studied at our center. Disc herniation at the L5-S1 level was documented by MRI or CT in all patients. All patients were studied bilaterally by DSSEPs at L5 and S1 before and after VAX-D therapy. All patients had at least 50% improvement in radicular symptoms and low back pain and three of them experienced complete resolution of all symptoms. The average pain reduction was 77%. The number of treatment sessions varied from 12 to 35. DSSEPs were considered to show improvement if triphasic characteristics returned or a 50% or greater increase in the P1-P2 amplitude was seen. All patients showed improvement in DSSEPs after VAX-D therapy either ipsilateral or contralateral to the symptomatic leg. Two patients showed deterioration in DSSEPs in the symptomatic leg despite clinically significant improvement in pain and radicular symptoms. Overall, 28 nerve roots were studied before and after VAX-D therapy. Seventeen nerve root responses were improved, eight remained unchanged and three deteriorated. The significance of DSSEP improvement contralateral to the symptomatic leg is emphasized. Direct compression of a nerve root by a disc herniation is probably not the sole explanation for referred leg pain. (Neurol Res 2001; 23:706-714)

Key words: lumbar radiculopathy      vertebral decompression      dermatomal somatosensory evoked potentials      low back pain      VAX-D therapy

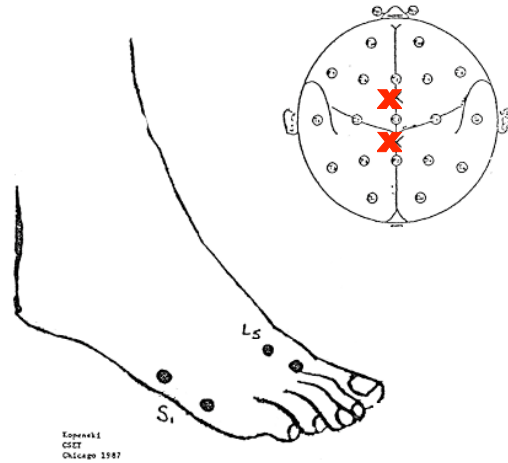
Improvements in low back and referred leg pain associated with a diagnosis of herniated disc, degenerative disc disease or facet syndrome have previously been reported after VAX-D therapy (1). In 71% of the 778 cases, the pain was reduced to 0 or 1 on a 0 to 5 scale. Improvements in mobility and activities of daily living were also noted. The average decrease in pain, plus or minus the standard error of the estimate, was 2.88 +/-0.05 units on a scale of 0-5, and a paired two-sample t-test shows that this pain decrease was at least 2.68 units with p<0.00005. The average increase in mobility was 1.17 +/- 0.03 on a 0-3 scale, and this value was at least 1.04 units with p<0.00005. Similarly, the average increase in the activity score was 0.96+/-0.04 units on a 0-3 scale, and this average improvement was at least 0.83 with p<0.00005. The coefficient of linear correlation (2) between mobility and pain scores was 0.72 and between pain and activity it was 0.60. The clinical improvement in pain, mobility and activities of daily living argues strongly that nerve root decompression can reasonably be expected to follow VAX-D therapy.

Lumbar disc decompression is clearly possible non-surgically through the application of effective lumbar distraction tensions. Gupta and Ramarao (3) treated 14 patients with prolapsed intervertebral disc syndrome with continuous traction and showed complete or partial resolution of the defects on epidurogram. Mathews (4) likewise showed reductions in disc herniations in two patients by epidurography accompanied by vertebral body separation of 2mm per disc space. Ramos and Martin (5) measured intradiscal pressure by connecting a cannula inserted into the patient's L4-5 disc space to a pressure transducer. Tensions applied by the VAX-D table were observed to decompress the nucleus pulposus significantly, to below -100 mm Hg.

Dermatomal somatosensory evoked potentials (DSSEPs) are an established and effective physiologic tool for assessing single nerve root function pre- and post- operatively (6,7,8,9,10,11) and are useful as well for monitoring potential acute nerve root injury during surgical procedures using intrapedicular fixation of the lumbosacral spine (12).

Dvonch et al (13) studied the root specificity of DSSEPs using myelograms and surgical findings as the standards and found the accuracy of DSSEPs to be 85.7% for lumbar radiculopathy when compared to myelograms and 87.5% when compared to surgery. Sensitivity was 0.93 and specificity was 0.86. Chi square analysis was applied and accuracy was defined as the ratio of all correct results to the total number of nerve root pairs tested. Bilateral DSSEPs were performed on each patient at L5 and S1. Each nerve root was compared to the contralateral root and differences in latency of more than 3 msec or amplitude differences of more than 75% were considered significant.

Overall, DSSEPs were shown to have an 86% accuracy in root specific diagnosis. The authors also concluded that since pain is a frequent accompaniment of root entrapment, DSSEP findings can provide information in addition to the structural abnormalities demonstrated by myelograms by offering a physiologic way of monitoring the sensory side of the nervous system. DSSEPs should thus be a useful adjunct in the selection of patients undergoing lumbar spine surgery.



**Figure 2: Electrode placement for dermatomal somatosensory evoked potentials at L5 and S1. The stimulating electrodes (on the foot) are shown as • and the recording electrodes (on the scalp) are shown as X.**

**PAIN LEVEL (0 to 10 scale)**

<b>PATIENT</b>	<b>BEFORE VAX-D</b>	<b>AFTER VAX-D</b>	<b># OF TREATMENTS</b>
<b>1</b>	<b>5</b>	<b>0</b>	<b>12</b>
<b>2</b>	<b>8</b>	<b>0-0.5</b>	<b>35</b>
<b>3</b>	<b>7-8</b>	<b>4</b>	<b>13</b>
<b>4</b>	<b>3</b>	<b>0</b>	<b>10</b>
<b>5</b>	<b>5</b>	<b>1</b>	<b>10</b>
<b>6</b>	<b>5-6</b>	<b>2</b>	<b>20</b>
<b>7</b>	<b>6-7</b>	<b>2</b>	<b>20</b>

**Figure 1. Pain levels and number of treatments for the seven patients.**

Scarff et al (14) performed DSSEPs on 38 consecutive patients with suspected disc herniation. These patients subsequently underwent myelography and surgery with verification of nerve root entrapment by disc herniation. For each patient, comparisons were made regarding latency and amplitude of the DSSEPs from the involved and uninvolved leg. Differences in latency of more than 3 msec measured from the peak positive wave or an amplitude reduction of 75% were considered significant. Of the 38 patients, 35 had abnormal evoked potentials for the specific root involved. One patient had abnormalities for the contra-lateral root and 2 patients with bulging discs had normal DSSEPs.

Similarly, Larson (15) utilized somatosensory evoked potentials (SSEPs) and DSSEPs in evaluating 66 patients with lumbar stenosis. Satisfactory recordings were obtained from stimulation of the medial (L5) and lateral (S1) aspects of the foot in 62 of the 66 patients. Onset latency remained unchanged but the amplitude of the initial portion of the evoked potential waveform diminished to 50% or less of control after walking, flexion or extension. These changes were reversible and the presence of these abnormal responses correlated with a good surgical result. Furthermore, 26 of these patients had predominantly only unilateral symptoms of the lower limb but bilateral evoked response abnormalities were seen.

**Materials And Methods**

DSSEPs were conducted at our center on seven consecutive patients suffering from mechanical low back pain with referred leg pain in either an L5 or S1 distribution or both. Clinically, patients with L5 radiculopathy experience pain in the back of the thigh, lateral calf and dorsum of the foot. Patients with S1 radiculopathy experience pain in the back of the thigh, back of the calf and lateral foot (17). Two patients had bilateral symptoms. All seven patients had disc bulging or disc herniation on MRI or CT at the L5-S1 level. Two of these patients had disc herniations at L4-5 and one patient (patient #2) had multilevel disc herniations with symptoms referring into the left S1 distribution only. The initial pain levels and numbers of treatments are shown in Figure 1.

Each patient underwent bilateral lower extremity DSSEPs at L5 and S1 immediately before and within two weeks after the completion of VAX-D therapy. Data was obtained using a Nihon-Kohden Neuro Pack #4 instrument. All patients were studied at our center by a certified technologist from Rasmussen Diagnostics, Woodstock, Georgia. The number of treatment sessions per patient varied from 10 to 35.

Dermatomal stimulation at L5 was done medial to the extensor hallucis tendon on each side with the ground reference over the anterior ankle. For S1, stimulation was done at the lateral aspect of the fifth metatarsal with the ground electrode over the ankle, as shown in Figure 2. Cortical electrodes were placed 3 cm anterior and posterior to Cz. Filter settings were set at 10 Hz to 250Hz. The rate of stimulation was 3 per second delivered as a square wave pulse of 0.2msec duration with intensities of 2.2 to 7.6 mA. Stimulation intensity varied somewhat between patients and was determined by beginning at a low level of stimulation and increased until the patient perceived a strong but not painful, tapping sensation. Two trials were performed on each root to verify that the waveform was reproducible. The number of stimulations per trial ranged from 150 to 300. The two trials were then averaged and the final waveform was smoothed using a 9-point running average. Each patient was studied consistently each time either supine or in a recliner. Room temperature remained constant at 72 degrees Fahrenheit and wakefulness was assured.

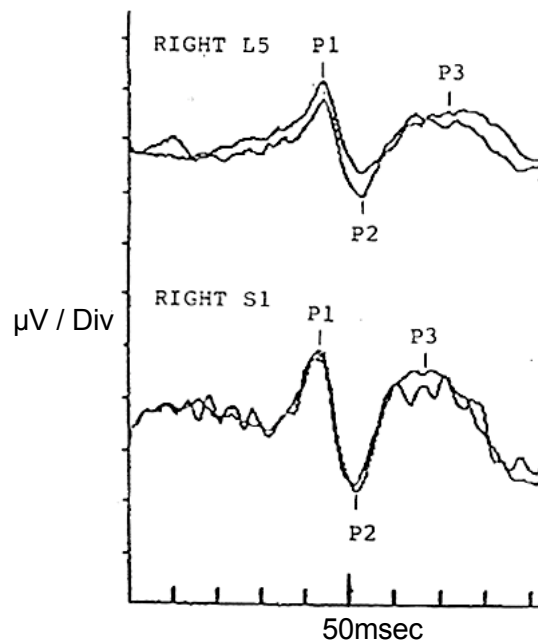


Figure 3: Typical DSSEP's showing averaged waveforms per site. The three 'peaks' are indicated by P1, P2 and P3.

Using this montage a signal-averaged triphasic cortical potential is normally to be expected from each site in an uninjured patient (6,18,19). Responses of greatest amplitude are possible by this arrangement of scalp electrode placement because the potentials are being measured in the vicinity of the sensory cortex contralateral to the side of the stimulus.

Compared to other cortical montages this placement also minimizes otherwise frequent contamination by action potentials from the temporalis muscle. The triphasic wave consists of an upgoing negative peak (P1), followed by a deep downgoing positive peak (P2) and finally an upward shoot past the baseline, again positive (P3). A typical response waveform is shown in Figure 3. All waveforms were printed in the same scale of 0.31 microvolts per division and 10msec per division to allow direct comparisons of waveform morphology at each nerve root before and after VAX-D therapy.

The authors theorized that the morphology of the waveforms would be distorted or suppressed prior to VAX-D therapy given that the duration of clinical symptoms ranged from 8 weeks to 60 months for the patients in this study. Treatment sessions were given Monday through Friday with patients under treatment from 2 to 7 weeks. This amount of time may have allowed nerve root functional recovery while the patient was receiving VAX-D therapy.

Our study is in contrast to previous studies in the literature which eliminated patients with poorly reproducible waveforms before surgery. Intra-operative studies have focused on latency delays or a sudden loss of the first component of the waveform as a sign of acute nerve root injury. Because VAX-D therapy is a treatment which may have cumulative benefit over time (1), the authors assumed that as nerve roots were decompressed, electrical transmission would improve but not necessarily return the DSSEP to a truly normal waveform.

We thus placed emphasis on the reconstitution of the waveform and its overall morphology, while evaluating DSSEPs generated in this study using latency and amplitude parameters consistent with the literature as well. Additionally, the literature has emphasized side to side comparisons at each nerve root level. This study compares each nerve root before and after VAX-D therapy.

Several quantitative measures of waveform quality were considered, including the amplitudes of the P1-P2 and P2-P3 portions of the waveform, their post-stimulus times of occurrence, and the presence or absence of P1, P2, and P3 “peaks” (positive or negative) in the waveform. However, for some waveforms it was not possible to distinguish with certainty between true peaks and noise artifacts. In this circumstance, the authors felt that it was more practical to consider the waveform as a whole, and decide if its quality increased or decreased significantly. The quality depends on the amplitudes, the presence or absence of P1, P2, and P3 peaks, and the ability to distinguish the waveform from the noise. The measure is subjective, so all the waveforms are shown in Figure 4, and are labeled as “better”, “worse”, or “same”. These decisions were made separately by the three authors and the technician, all of whom agree with this labeling.

## **Results**

All the DSSEPs, before and after VAX-D therapy, are shown in Figure 4. Clinically, all patients in our study were symptomatic before VAX-D therapy. Low back and referred leg pain were reduced by over 50% in each patient after VAX-D therapy and three were essentially pain free. The average pain reduction was 77%. Before VAX-D therapy, DSSEP waveform morphology was often abnormal, with absence of the first peak (P1) being most typically seen.

This is not an unexpected finding since temporal dispersion of axonal volleys will affect early cortical DSSEP peaks, resulting in their diminution or loss without the loss of later peaks. It has been postulated that the resiliency of later peaks is due to the cerebral cortex functioning as an integrator, resynchronizing the incoming inputs (18). For those DSSEPs in which P1 was present before and after VAX-D therapy, a P1 latency was measured as well as a P1-P2 amplitude. Following the criteria of Scarff et al (14) for latency and Larson (15) for amplitude, a difference in latency of 3 msec or greater or an amplitude change of 50% or greater was considered significant. No significant changes were seen on average in either latency or amplitude in our study for those DSSEPs possessing a distinct P1 before and after VAX-D therapy.

PATIENT	LEG PAIN DISTRIBUTION	LEFT		RIGHT	
		L5	S1	S1	L5
1	Left S1	B	B	B	B
2	Left S1	W	W	B	B
3	Left L5-S1	B	S	B	S
4	Right S1	S	B	W	S
5	Right L5	B	B	S	S
6	Right + Left				
	L5 + S1	B	S	S	B
7	Right + Left				
	L5 + S1	B	B	B	B

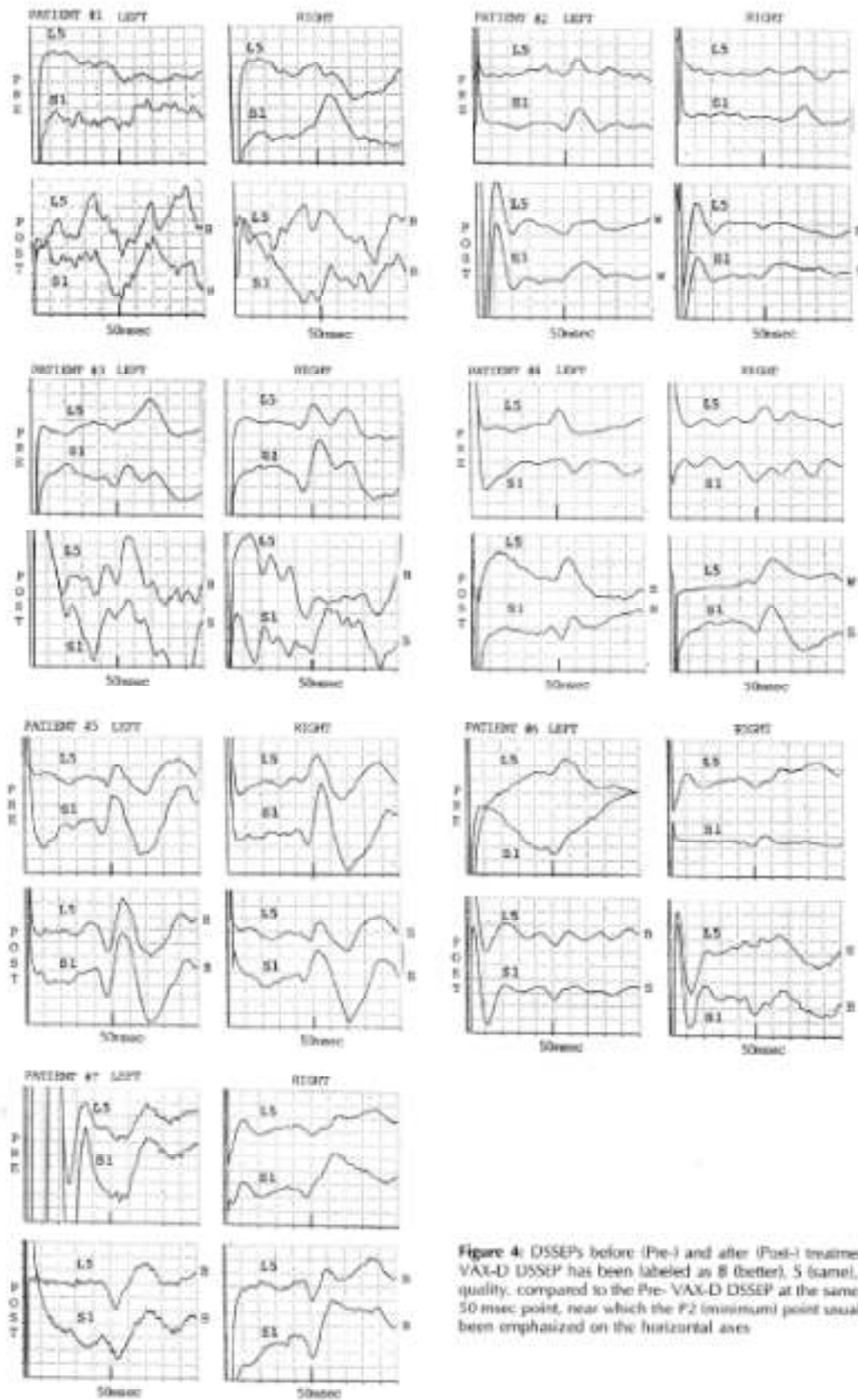
Figure 5. Pain distribution before treatment and DSSEP results after treatment

If there were no intrinsic difference between the data before treatment and the data after treatment, then the probability that the DSSEP response would improve would be equal to the probability that it would get worse. There would also be some probability that the quality of the response would neither increase nor decrease but would remain the same, within the limits of our ability to estimate the quality of these waveforms.

In Figure 5, eight of the 28 responses did not change significantly, 17 improved, and three were worse after treatment. The probability that results this good would be obtained by chance is less than 0.0013, i.e.  $p < 0.0013$ , according to the cumulative binomial distribution, as shown below. If it were true that, for the 20 responses that changed, a change for the better (B) were as likely as a change for the worse (W), then

$$\begin{aligned}
 P(17 \text{ of the } 20 \text{ are B}) &= \frac{20!}{(17! \ 3! \ 2^{20})} = 0.001087189 \\
 P(18 \text{ of the } 20 \text{ are B}) &= \frac{20!}{(18! \ 2! \ 2^{20})} = 0.000181198 \\
 P(19 \text{ of the } 20 \text{ are B}) &= \frac{20!}{(19! \ 1! \ 2^{20})} = 0.000019073 \\
 P(\text{all } 20 \text{ are B}) &= \frac{20!}{(20! \ 0! \ 2^{20})} = \underline{0.000000954} \\
 \text{Sum} &= 0.001288414
 \end{aligned}$$

The sum of these gives the probability that 17 or more of the 20 would be better by chance:  $P(17 \text{ or more are B}) = 0.001288414$ . So  $p < 0.0013$  that results as favorable as those found in this study would occur by chance. Statistically, these results are very significant.



**Figure 4:** DSSEPs before (Pre-) and after (Post-) treatment. Each Post-VAX-D DSSEP has been labeled as B (better), S (same), or W (worse) quality, compared to the Pre-VAX-D DSSEP at the same location. The 50 msec point, near which the P2 (minimum) point usually occurs, has been emphasized on the horizontal axes.

## **CASE REPORTS**

### **Patient #1**

A 48 year old male with a five-month history of chronic low back and left leg pain predominantly in an S1 distribution. Lumbar MRI revealed a moderate left paramedian herniated nucleus pulposis compressing the S1 nerve root. The patient received 12 VAX-D treatments and experienced complete resolution of low back and left leg pain.

### **Patient #2**

A 54 year old county school psychologist with an eight week history of low back pain and left S1 radiculopathy. He had a previous episode of left leg sciatica several years before which resolved with bed rest and medication. Lumbar CT revealed a large left paracentral herniated nucleus pulposis at L5-S1 compressing the left S1 root. Additionally, a moderate central herniated disc was seen at L4-5 resulting in moderate spinal stenosis and a small left paracentral disc herniation was seen at L3-4. He underwent a total of 35 VAX-D treatments and experienced a greater than 90% reduction of his low back and left leg pain.

### **Patient #3**

A 31 year old female with a 2 year history of chronic low back pain and intermittent left leg pain following an L5 and S1 distribution. Lumbar CT showed a contained central annular bulging of the L3-4 and L4-5 discs with no significant underlying neural compromise, as well as a small to moderate midline herniation at L5-S1 causing some effacement of the underlying thecal sac. She completed 13 VAX-D sessions with a 50% reduction in pain and experienced a subjective increase in mobility.

### **Patient #4**

A 48 year old male with a 60 month history of chronic low back pain and right leg pain in an S1 distribution. Lumbar MRI showed desiccation and degenerative changes of the L5-S1 disc with a right sided herniation causing effacement of the right S1 root. Minimal bulging of the L3-4 and L4-5 discs was noted as well. After ten VAX-D treatments all pain was eliminated.

### **Patient #5**

A 56 year old female with a 9 month history of chronic low back pain and occasional episodes of right sided sciatica in an L5 distribution. Lumbar MRI showed degenerative disc disease at L4-5 and L5-S1 with a mild diffuse disc bulge at L4-5 encroaching upon the right L5 root. The patient experienced an 80% reduction of pain after her tenth VAX-D treatment.

### **Patient #6**

A 23 year old male with a 10 month history of low back pain after a lifting injury at work. Pain and numbness were present intermittently in both legs in an L5 and S1 distribution but more severely affected the left leg. Lumbar MRI scan showed degenerative disc disease at L4-5 and L5-S1 with a left sided herniated disc at L5-S1. After twenty VAX-D treatments he no longer experienced any numbness in his legs and his pain was reduced by 50%. He elected to stop further treatments in favor of returning to work.

### **Patient #7**

A 33 year old EMT with a 38 month history of low back pain associated with periods of either right, left or bilateral leg pain and numbness in an L5 and S1 distribution. Predominantly the right leg was most symptomatic at the time she underwent VAX-D therapy. A lumbar MRI before treatment showed a degenerated L4-5 disc with a left paracentral herniation indenting the thecal sac. At L5-S1 the disc was degenerated with a small left paracentral herniation without nerve root



compromise. The patient underwent 20 VAX-D treatments with complete resolution of leg numbness and a 70% reduction in low back and leg pain.

## Discussion

We know that VAX-D is a safe and generally successful treatment of low back pain associated with lumbar disc herniation, degenerative disc disease, or facet syndrome. VAX-D was designed with a primary purpose to relieve low back pain with or without radiculopathy. Surgery, oftentimes, is focused primarily on nerve root decompression to relieve radicular pain and any improvement in back pain follows as a secondary benefit. This secondary benefit occurs despite the fact that discectomy and laminectomy involve further disc and spine disruption. The literature is clear that not all patients benefit by surgical nerve root decompression and also that surgical patients on average fare no better long term than patients who are managed conservatively (20,21,22,23 24).

The present study used DSSEPs to provide an objective means of measuring a physiologic cortical manifestation of nerve root decompression. In 1994 using disc manometrics, Ramos provided clear documentation that negative intradiscal pressure changes down to  $-150$  mm Hg were achieved with VAX-D treatment.

Tilaro and Miskovich (25), using a CPT neurometer, showed that peripheral peroneal and sural nerve distribution sensation were improved in 27% or returned to normal in 67% of 17 patients with radiculopathy symptoms after VAX-D treatment. They used the CPT Neurometer to deliver a sinusoidal electrical stimulus. The threshold of perception was defined as the minimal amount of stimulus required to evoke a sensation at least 50% of the times it was presented. Results were taken three times at each site and were reliable, i.e., statistically they could not have been fabricated by a patient. Tilaro and Miskovich reasoned that improvement with VAX-D must have reflected nerve root decompression because no other change in function of the peroneal and sural nerves, spinal cord, brainstem or cerebral cortex would be expected. Neurometer measurements rely on the patient's subjective experience (perception) of sensory stimulation. Perception involves cortical activation and integration. It is a conscious subjective response.

Somatosensory testing, in general, assesses the electrophysiology of the pathway to the brain's cortex as a consequence of a sensory experience such as vision, hearing, or extremity sensation. Scalp electrodes pick up cortical activity which is then signal averaged to create a waveform. Our results extend the work of Ramos and Tilaro. We chose DSSEPs to isolate L5 and S1 root function by dermatomal stimulation. Further, results were taken bilaterally such that each patient in essence served as his or her own control. Four roots were monitored for all patients. Restored waveforms had a triphasic appearance which is normal and expected for the method of recording we used. DSSEP's are used widely for monitoring potential spinal cord or nerve root injury during spinal surgery, particularly when there is a concern about injuring nerve roots.

In this study, we found that multiple nerve roots appear to be decompressed in most of the patients, which fits nicely with the data of Tilaro and Miskovich. Their neurometer measurements were taken over the peroneal and sural nerves, which are relatively large. Although these nerves derive from a limited number of nerve roots, they are not pure. Stimulation of the peroneal nerve sends impulses through L4 and L5 roots. Likewise, stimulation of the sural nerve sends impulses through L5 and S1. It may be that multiple nerve root decompression was responsible for the large improvements in the perception thresholds measured by Tilaro and Miskovich.

Clinical implications that can be derived may have importance as to how we view the low back and what we may think is the main source of pain for a particular patient. Patient clinical histories and examinations suggest that nerve roots are not involved in isolation but that adjacent

nerve roots and even contralateral changes may exist to account for symptoms that overlap dermatomes or are bilateral despite a unilateral lesion. The DSSEPs reviewed here provide physiologic evidence that this possibility not only exists but is likely.

The best surgical outcome to be expected occurs when spine imaging is consistent with symptoms and clinical findings. These patients tend to do well with surgery and therefore one might conclude that nerve root decompression has something to do with why leg pain in particular responds. Other patients do less well, particularly when symptoms and clinical findings are inconsistent with the results of diagnostic imaging. Possible explanations relate to irreversible nerve root injury from a ruptured disc, epidural fibrosis and other poorly understood reasons.

The remarkable improvements following VAX-D therapy (71%) for a variety of pathologies (1) suggests some possibilities for these “otherwise poorly understood reasons.” Our study suggests that VAX-D exerts its benefit at more than one level ipsilateral and contralateral to the direction of disc herniation. Evidence is provided that multiple root abnormalities by DSSEP may be present despite one structural lesion by MRI. Although clinicians assume that the consequences of such structural pathology is an important source of pain, our present results raise the possibility that such pathology may not be the main cause of pain but may allow consequent or subsequent changes to become the primary source of pain for an individual patient. Tsai et al (26) studied 33 patients with intraoperative DSSEPs undergoing micro-decompression for single level, unilateral lumbosacral radiculopathy. Nineteen patients had acceptable DSSEPs at baseline with 13 of these 19 patients having an abnormal DSSEP for the symptomatic nerve root defined as a side-to-side latency asymmetry of greater than 5% before surgery. Four patients had DSSEP side-to-side latencies within 5% at each nerve root level and 2 patients had poorly reproducible evoked responses on the symptomatic side. All latency asymmetries resolved and improved waveforms were seen in the 2 patients with poor evoked responses before surgery.

Despite apparently successful nerve root decompression, clinical outcome at 3 months was good to excellent in 13 patients, fair in 4 patients and poor in 2 patients. This may at first seem surprising but do we really know what is the most important source of pain and whether it relates to the primary event such as a disc herniation or does it follow as a consequence? In our study, all patients were clinically improved but only one showed contralateral improvement by DSSEP. The authors wonder what the outcome would have been if the patient had been operated on ipsilaterally. With the above analysis, we now have an explanation for overlapping dermatomal complaints, bilateral symptoms, and sometimes pain going down “the wrong leg”- meaning that the MRI shows a disc herniation directed opposite to the symptomatic leg.

We suggest that VAX-D therapy effectively manages mechanical low back pain with or without referred leg pain through spine segment mobilization. Spine segment motion integrity is a crucial concept and probably best explains the correlation previously found between reduced pain and improved gross spine mobility subsequent to VAX-D therapy (1). A spine motion segment consists of two vertebral bodies with an intervening disc and all attached and enclosed structures (27). Segment motion normally is dynamic with flexion, extension, torsion, and tilting often combined simultaneously allowing pain-free movement in a normal spine. This occurs normally without nerve root impingement despite even extreme spine flexion and extension seen in gymnasts and contortionists. Furthermore, it is known that the spinal cord can adapt to length changes of the spinal canal because the cord itself is folded when the spine is in a neutral position and will unfold during flexion and can fold further during spine extension. The nerve roots follow the spinal cord but do not fold and unfold (27). It is the ability of the vertebra to translate and rotate upon each other that provides slack to the nerve roots. Impairments here stymie functional compensations to reduce “the pressure on nerve roots” as the spine is loaded by weight-bearing activities.

VAX-D therapy helps to restore mobility and allows for a return of dynamic functional compensation. A natural consequence of disc injury is to accelerate “natural” fusion of the segment. If the segment “fuses” in a position that allows enough room in the lateral recess, central canal, and neural foramina –then there may be no pain. If however, such fusion is less harmonious there will be pain plus lost motion. VAX-D is unique in its position to alter the reactive process leading to symptomatic bony fusion whereby osteophytic changes are seen on the anterior and posterior aspects of the vertebral endplates. Again Gose, Naguszewski and Naguszewski (1) showed a clear and strong correlation between increased mobility and decreased pain reported after VAX-D therapy. This dynamic compensation is presumed to be the result of spinal reflexes that function specifically to maintain proper alignment of stacked spine motion segments.

These spinal reflexes are protective against nerve root injury and can be acted upon by higher centers to facilitate smooth, safe and effective voluntary movement. We know that the erector spinae muscles are “ratcheted” on the spine like shingles on the roof of a house to allow accordion-like motion. The transverse spinal muscles span one, two, three or more segments (28). Spinal reflexes are in place to coordinate all of these muscles to allow full range of motion without nerve root impingement. With acute lumbar injuries, the spinal reflexes may induce sustained muscular contraction resulting in radiographic straightening of the lumbar spine and immobilization of one or more lumbar motion segments. Sustained muscular contraction for weeks may lead to adhesive capsulitis of the facets, perpetuating motion segment immobility despite eventual resolution of muscular spasm. Additionally, the persistence of contracted musculature may eventuate into contracture reducing mobility of the affected lumbar motion segment. Such focal contracture so to speak, is myofascial fusion. We argue that VAX-D therapy is best suited to release such contracture.

With degenerative disc disease there is a loss of disc height. Disc height is crucial in determining neural foraminal vertical height. Ligamentum flavum hypertrophy may develop and encroach upon the nerve roots posteriorly. End plate changes and facet changes can also encroach on the neural foramina anteriorly and posteriorly respectively. All these changes limit the extent to which neuro-protective spinal reflexes can relieve pressure on nerve roots. The spine motion segment loses dynamic range and the small “shingled” muscles cannot act to cause a dynamic translation of the segment and reduce pressure on the neuro-vascular bundle. At this point axial loading of the motion segment is poorly tolerated because there is no dynamic reserve to allow minute translation, rotation or tilting of the neural foramen. The neural foramen is fixed in anterior and posterior diameter with further narrowing occurring vertically as the disc fatigues and bulges under axial loading. Disc fatigue is probably time dependent under sustained axial loading and accounts for the clinical presentation of patient complaints that they cannot stand or sit for more than a minute or two (static loading) before worsening radicular symptoms occur. Walking relieves symptoms at least initially by providing external dynamic weight shifting across the affected lumbar motion segment.

Typically, patients with mechanical back pain experience an increase in their low back pain and radicular symptoms during times when their spine is asked to support body weight such as during prolonged sitting or standing. The pain generators for these patients may be a herniated disc, reduced neuroforaminal size secondary to degenerative disc disease or facet syndrome. It has been shown that lumbar traction can produce a “distraction” or increased separation of 1 to 2 mm between each pair of lumbar vertebra (4) as well as reduce the size of disc herniations (3,4). Furthermore,

Twoney (29) studied the effects of traction on the lumbar spines of cadavers stripped of the paraspinal musculature and found residual lengthening of the lumbar spine after release from sustained traction. This residual lengthening was seen in those spines in which degenerative disc changes were prominent and may relate to disc rehydration since the spines were continuously

bathed in normal saline throughout the experiment. In-vivo, we do not know whether “traction” physically results in sustained lengthening of the spine segment after a distraction tension has been released but we do know that lengthening of the lumbar spine segments does occur during applied traction. Lumbar distraction may improve facet joint mobility by releasing an entrapped interarticular meniscus or fold of the capsule or synovial membrane (30) and may restore spine segment mobility by stretching and releasing erector spinae muscles contracted by sustained spasm.

The VAX-D table represents a technological advance in the application of effective lumbar distraction tensions with improved patient tolerability and satisfaction compared to previous lumbar traction devices requiring thoracic corsets or the application of heavy static weights (1). VAX-D therapy has been shown to decompress the nucleus pulposus significantly, to below  $-100$  mm Hg (5). The intervertebral discs separate the vertebra with the annulus fibrosus containing the nucleus pulposus by its attachment to the vertebral margins. The negative intradiscal pressures generated by VAX-D suggests that an increased separation of the vertebra occurs during VAX-D therapy, as it did with older lumbar traction devices.

Traditionally, the term “decompression” as applied to the spine has referred to nerve root decompression. Surgery for decompression has been directed at the radiographic sites of nerve root entrapment including the removal of herniated disc material or osteophytes at the lateral recess or neural foramen. This study, however, has demonstrated that most of the patients suffering from chronic low back pain and radiculopathy had multiple nerve root abnormalities based on abnormal DSSEPs, many of which would not be predicted radiographically. Successful treatment by VAX-D therapy resulted in clinical reduction in pain and improved DSSEP waveforms suggesting that nerve root decompression is occurring at multiple levels. With VAX-D therapy, the concept of “decompression” can now be broadened to include the lumbar spine motion segment itself, with decompression not only of the nerve roots, but also the disc, facet joints and potentially, the paraspinal musculature as it is stretched and muscular spasm resolves.

An acute disc injury and discogenic pain may often be the primary process leading to low back pain and lumbar radiculopathy. Biochemical and inflammatory changes within the disc contribute to the patient’s pain. The negative intradiscal pressures generated by Vax- D therapy may promote healing as nutrients, oxygen and water are transfused into the disc which is otherwise an avascular structure, dependent predominantly upon a diffusion gradient as the main mechanism of transport of these vital substances into the disc (31). However, chronic low back pain is often accompanied by lost mobility and secondary consequences such as nerve root dysfunction above and contralateral to the disc herniation, as indicated by this study.

For any given patient with low back and referred leg pain, we cannot predict with certainty which cause has assumed primacy. Therefore surgery, by being directed at root decompression at the site of the herniation alone, may not be effective if secondary causes of pain have become predominant. Vax- D therapy however addresses both primary and secondary causes of low back and referred leg pain. We thus submit that VAX-D therapy should be considered first, before the patient undergoes a surgical procedure which permanently alters the anatomy and function of the affected lumbar spine segment.

## REFERENCES

1. Gose EE, Naguszewski WK, Naguszewski RK, Vertebral axial decompression therapy for pain associated with herniated or degenerated discs or facet syndrome: An outcome study. *Neurological Research*, 1998, Volume 20, April pp. 186-190.
2. Gose EE, Johnsonbaugh R, Jost S. *Pattern Recognition and Image Analysis*, Upper Saddle River, NJ: Prentice Hall PTR, 1996: pp.1- 484.
3. Gupta RC, Romarao SV. Epidurography in the reduction of lumbar disc prolapse by traction. *Arch Phys Med Rehabilitation* 1978; 59: 322-327.
4. Matthews JA. Dynamic discography: A study of lumbar traction. *Ann Phys Med* 1968; IV: 275-279.
5. Ramos G, Martin W. Effects of vertebral axial decompression on intradiscal pressure. *J. Neurosurg* 1994; 81: 350-353.
6. Aminoff MJ, Goodin DS, Parry GJ, Barbaro NM, Weinstein PR, Rosenblum ML. Electrophysiologic evaluation of lumbosacral radiculopathies: electromyography, late responses and somatosensory evoked potentials. *Neurology* 1985; 35: 1514-8.
7. Eisen A, Hoirsch M, Moll A. Evaluation of radiculopathies by segmental stimulation and somatosensory evoked potentials. *Can J Neurol Sci* 1983; 10: 178-182.
8. Cohen BA, Huizenga BA. Dermatomal monitoring for surgical correction of spondylolisthesis. *Spine* 1988; 13: 1125-8.
9. Katifi HA, Sedgewick EM. Somatosensory evoked potentials from posterior tibial nerve and lumbo-sacral dermatomes. *Electroencephalogr Clin Neurophysiol* 1986; 65: 249-59.
10. Herron LD, Trippi AC, Gonyeau M. Intraoperative use of dermatomal somatosensory-evoked potentials in lumbar stenosis surgery. *Spine* 1987; 12: 379-83.
11. Machida M, Asai T, Sato K, Toriyama S, Yamada T. New approach for diagnosis in herniated lumbosacral disc: Dermatomal somatosensory evoked potentials (DSSEPs) *Spine* 1986; 11: 380-4.
12. Toleikis JR, Carlvin AO, Shapiro DE, Schafer MF. The use of dermatomal evoked responses during surgical procedures that use intrapedicular fixation of the lumbosacral spine. *Spine* 1993; 18: Number 16: 2401-2407.
13. Dvonch V, Scarff T, Bunch WH, Smith D, Boscardin J, Lebarge H, Ibrahim K. Dermatomal somatosensory evoked potentials: Their use in lumbar radiculopathy. *Spine* 1984; 9: No 3: 291-293.
14. Scarff TB, Dallman D, Toleikis JR, Bunch WH. Dermatomal somatosensory evoked potentials in the diagnosis of lumbar root entrapment. *Surgical Forum* 1981; 32: 439-291.
15. Larson SJ. Somatosensory evoked potentials in lumbar stenosis. *Surgery, Gynecology and Obstetrics* 1983; 157: 191-196.
16. Scarff TB, Toleikis JR, Bunch WH, et. al.: Dermatomal somatosensory evoked potentials in children with myelomeningocele. *Z Kinderchar Grenzgeb* 28: 384-387, 1979.
17. Patten J. *Neurologic Differential Diagnosis*. New York: Springer-Verlag, 1987: p.210-211.
18. Kimura J. *Electrodiagnosis in Diseases of Nerve and Muscle: Principles and Practice*. Edition 2. Philadelphia: F.A. Davis Company, 1989: p.375-414.
19. Larson SJ, Sances A, Christenson PC. Evoked somatosensory potentials in man. *Arch Neurol* 1966; 15: 88-93.
20. Weber H. Lumbar disc herniation. A controlled prospective study with ten years of observation. *Spine* 1983; 2: 131-9.
21. Hakelius A. Prognosis in sciatica. *Act Orthop Scand (Suppl)* 1970; 129: 1-76.
22. Saal JA, Saal JS, Herzog R. The natural history of lumbar intervertebral disc extrusions treated non-operatively. *Spine* 1990; 683-86.
23. Saal JA, Saal JS. Non-operative treatment of herniated lumbar intervertebral disc with radiculopathy. An outcome study. *Spine* 1989; 14:43 1-37.

24. Bush K, Cowen N, Kaatz D, Gishen P. The natural history of sciatica associated with disc pathology. *Spine* 1992; 17: 1205-1212.
25. Tilaro F, Miskovich D. The effects of vertebral axial decompression on sensory nerve dysfunction. *Canadian Journal of Clinical Medicine* 1999; Vol 6 No 1: 2-7.
26. Tsai RY, Yang RS, Nuwer MR, Kanim LE, Delamarter RB, Dawson EG. Intraoperative dermatomal evoked potential monitoring fails to predict outcome from lumbar decompression surgery. *Spine* 1997 Sep 1; 22 (17): 1970-5.
27. Anderson GBJ, McNeill TW. *Lumbar Spine Syndromes Evaluation and Treatment*. New York: Springer-Verlog Wien, 1989: p 5-15.
28. Kirkaldy-Willis WH, Burton CV. *Managing Low Back Pain*. 3rd Edition. New York: Churchill Livingstone, 1992 p21-22.
29. Twoney LT. Sustained lumbar traction: An experimental study of long spine segments. *Spine* 1985; 10: 146-149.
30. Kos J, Wolf J: Inter-vertebral menisci and their possible role in vertebral blockages. *Chartered Society Physiotherapy Newsletter* 4-5, 1972.
31. Ballard WT, Weinstein JN. Biochemistry of the intervertebral disc. In: Kirkaldy-Willis WH, Burton CV, eds. *Managing Low Back Pain*, New York: Churchill Livingstone, 1992: p. 39-48.