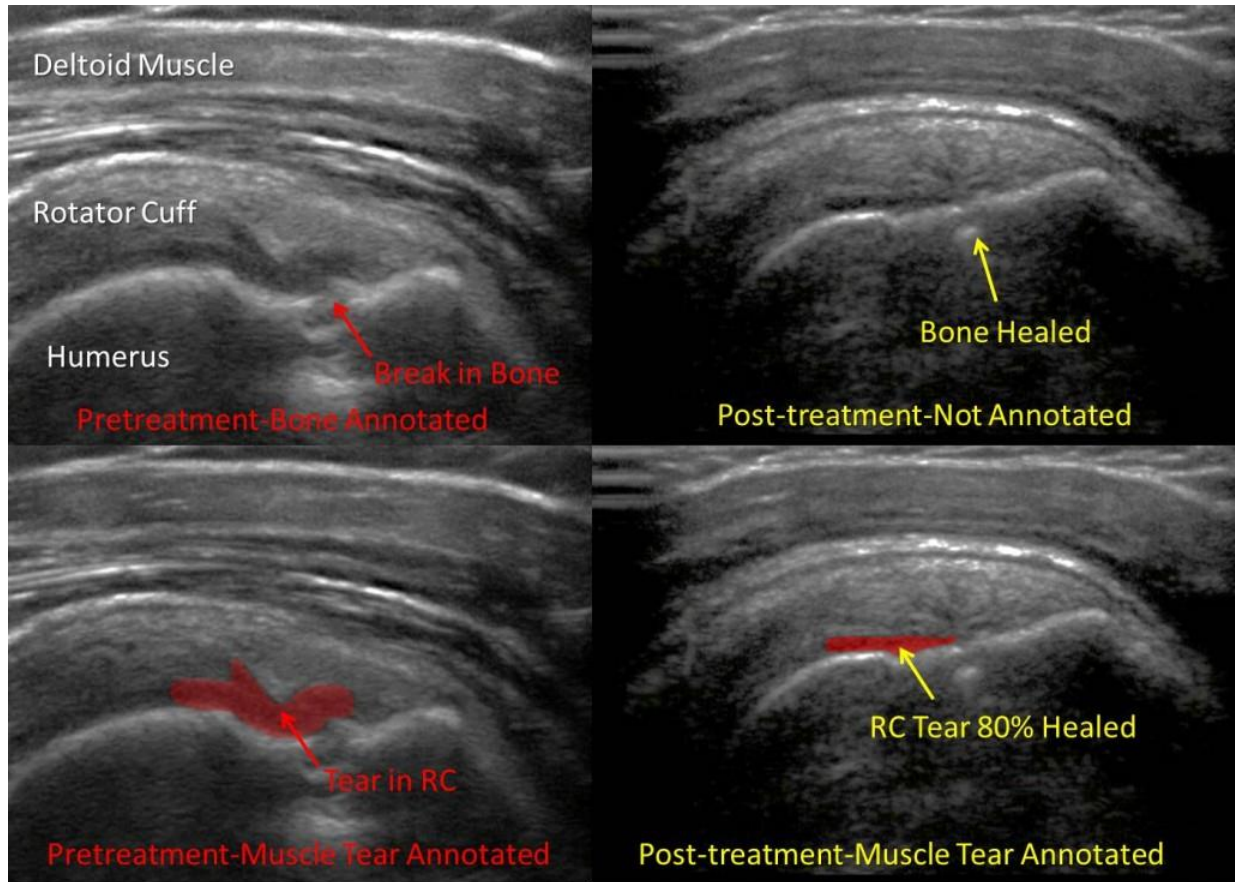


# Healing a Shoulder Rotator Cuff Tear in a Physical Therapist with Stem Cells



[Rotator cuff tears can be difficult to heal and shoulder surgery can have high complication rates.](#) In addition, [rotator cuff repair surgeries are often associated with long recovery and rehab times \(think blue pillow immobilizer\).](#) Here we present a case of a patient (EZ) who had a 2-3 year history of shoulder pain and after an MRI was told he needed surgery to repair the rotator cuff tear. The patient was a physical therapist, so he knew about [shoulder rotator cuff tear non-surgical options and wanted to try and avoid more invasive surgery.](#) [Shoulder rotator cuff tear injected under active ultrasound guidance](#) shown here. The patient underwent the Regenexx-PL and Regenexx-SCP injection procedures. These two are different and this will be a good discussion of the differences. [Regenexx-PL](#) is platelet lysate-our doctors crack open the platelets to get all of the important growth factors out to be immediately available to the stem cells. This is different than PRP (platelet rich plasma) which has intact platelets and acts as a timed release of growth factors. [While PRP \(platelet rich plasma\) can be very helpful at times,](#) when getting stem cells to grow, our lab experiments have shown that PRP under performs platelet lysate. The [Regenexx-SCP procedure uses a lab processed platelet preparation where the smaller blood circulating stem cells are preserved.](#) The result? The images above are from an ultrasound of the shoulder (sagittal cuts with a Sonosite M-Turbo in MSK mode). The pre-treatment pictures are

on the left (same pictures stacked on the left-one annotated for problems in the bone and one annotated for problems in the muscle). On the right, again the same image stacked, from two months after the first image. Note the break in the bone and the rotator cuff tear in the pre-treatment images and then the repair of the bone and much less prominent rotator cuff tear in the post-treatment images. The patient now reports no pain in the front of the shoulder with movement overhead. Throwing a softball and playing volleyball is now not painful. Overall improvement is noted at 90%.