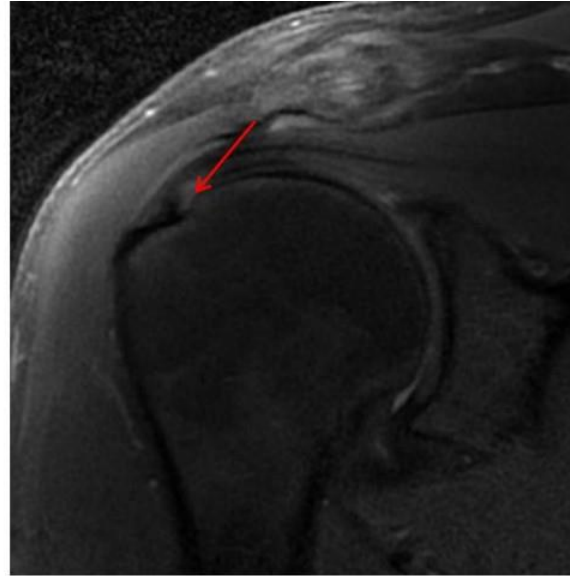
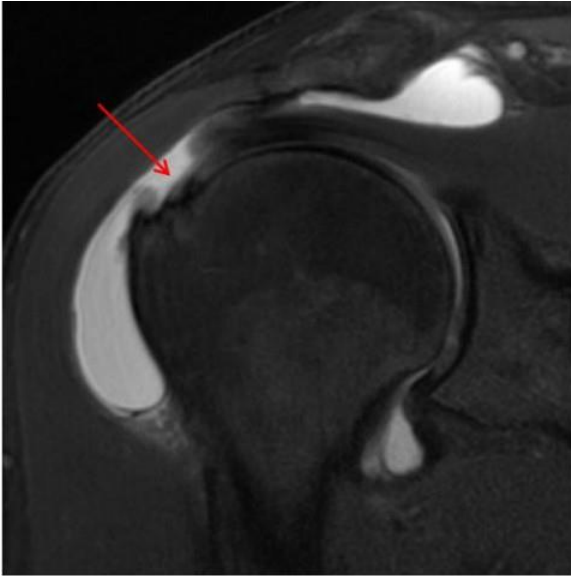


Update: Severe Shoulder Rotator Cuff Tear treated with Stem Cells



JS is a 54 year old active male with 1 year of pain who presented to the Centeno-Schultz clinic in 3/2010. He underwent 2 injections under ultrasound guidance with Regenexx SD. Initial MRI: 1/7/11, follow up: 11/2/11.

Stem cells for a severe shoulder rotator cuff tear? [I've previously blogged on JS, the patient we treated with Regenexx-SD despite a severe rotator cuff tear.](#) Since the tear in the rotator cuff was full thickness and retracted, we didn't know if we could help, but this patient was adamant about avoiding surgery. [His concern with shoulder surgery was based on the new data showing that it may not be all that effective.](#) In addition, he was a dedicated weight lifter and was also concerned that he'd never be able to return to the sport he loved. At my last update on JS, we only had his before and after ultrasound images, now we've received his before and after MRI images. He's now almost a year out from his shoulder stem cell injections. The improvement due to precision injections of his own stem cells is amazing. Note the large gap in the rotator cuff on the left (red arrow). The same area is now healed in the after MRI image on the right. JS did require a specialized treatment and bracing protocol unique to the Regenexx procedures and developed by Dr. Hanson. This is an example of [Interventional Orthopedics](#) at it's best-a procedure performed through a needle that used to require a surgery that allows the patient a quicker recovery and less downtime-a true shoulder surgery alternative!